

OSTEOSET® 2 DBM Bone Graft Substitute
**Treatment of Nonunion
With OSTEOSET® 2 DBM Pellets**

Ross Wilkins, MD

*Presbyterian St. Luke's Hospital, Institute for Limb Preservation
Denver, CO*

Figure 1 | pre-op

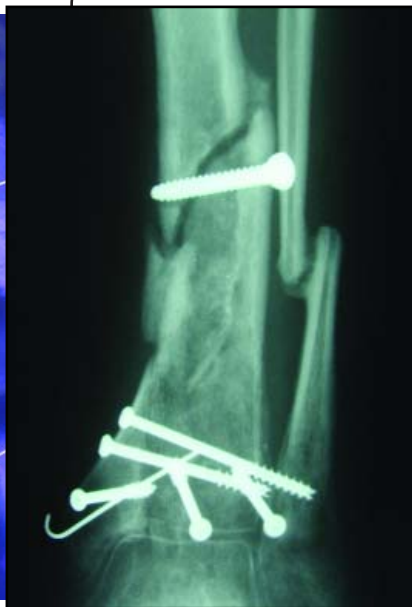

Figure 2 | pre-op

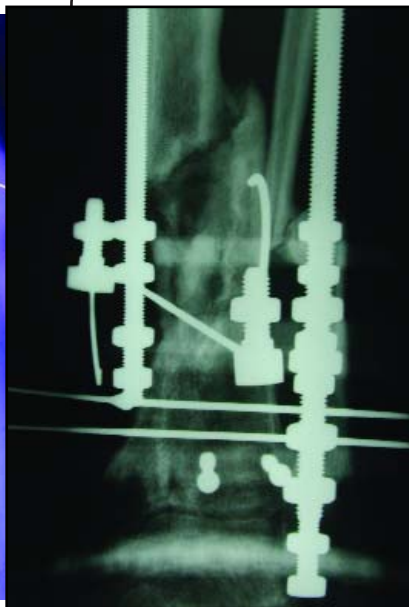
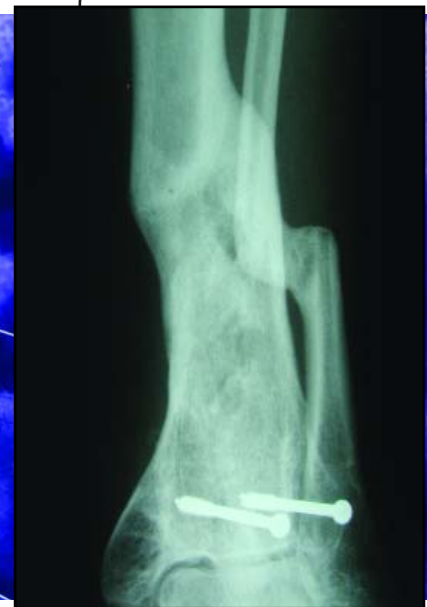

Figure 3 | post-op 10 months



CASE ONE | 24 year-old male

This 24 year old male was involved in a moving vehicle rollover. After 24 months and 4 surgeries, union of his distal tibia was not achieved.

At 24 months hardware was removed and the patient was placed in an external fixator, then grafted with OSTEOSET® 2 DBM Pellets. The graft material was inserted so as to bridge between the healthy bone on either side of the defect.

At 10 months post-op, the fixator was removed and the patient had achieved complete union.

OSTEOSET® 2 DBM Bone Graft Substitute

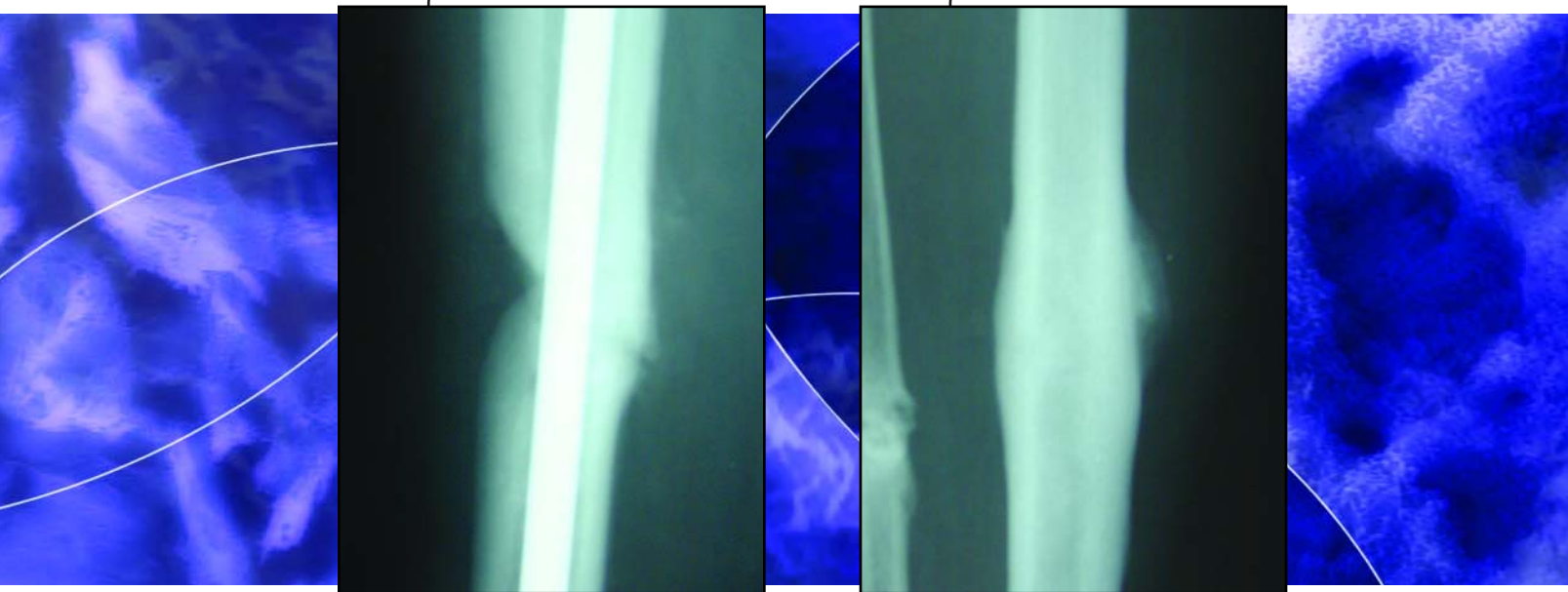
Treatment of a Tibial Nonunion With OSTEOSET® 2 DBM Pellets

Ross Wilkins, MD

Presbyterian St. Luke's Hospital, Institute for Limb Preservation
Denver, CO

Figure 1 | pre-op

Figure 1 | post-op 11 months



CASE TWO | 46 year-old female smoker

This 46 year-old female smoker presented with a previously infected tibial nonunion. Patient had failed two attempts with IM rodding and autograft. A new rod was inserted and the tibia was grafted with OSTEOSET® 2 DBM Pellets.

Eleven months after treatment with OSTEOSET® 2 DBM Pellets, the nonunion was healed and the rod was removed.



Wright Medical Technology, Inc.

5677 Airline Road
Arlington, TN 38002
901.867.9971 phone
800.238.7188 toll-free
www.wmt.com

Wright Cremascoli Ortho SA

Zone Industrielle la Farlecle
Rue Pasteur BP 222
83089 Toulon Cedex 09
France
011.33.49.408.7788 phone

™Trademarks and *Registered marks of Wright Medical Technology, Inc.
Covered by one or more of the following US Patents 5,614,206; 5,807,567; 6,030,636. Patents pending
©2004 Wright Medical Technology, Inc. All Rights Reserved.