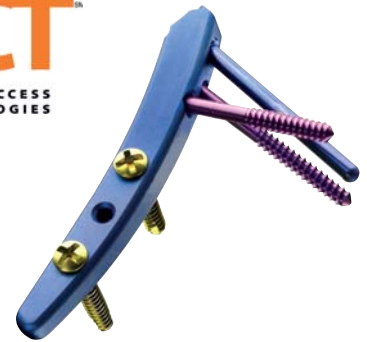
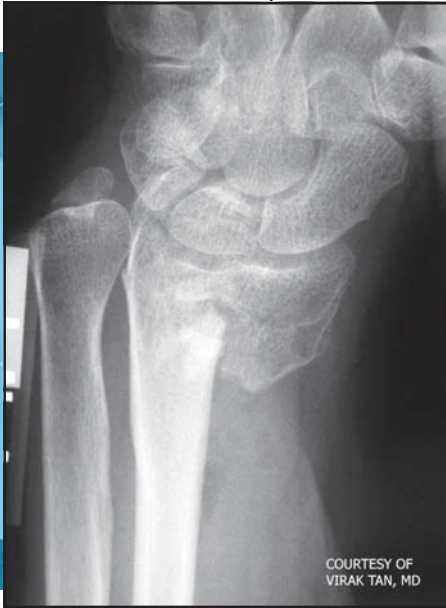


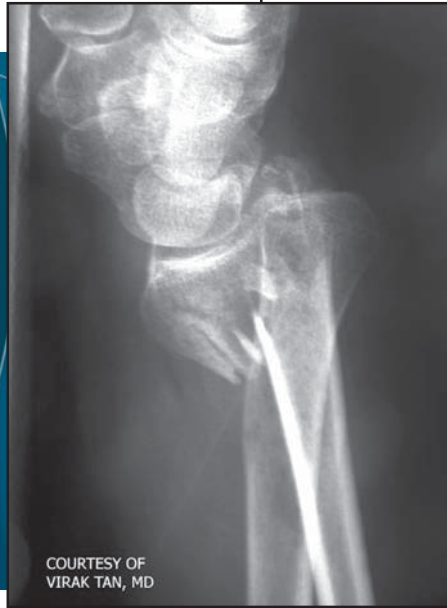MICRONAIL™ Intramedullary Fixation 82-Year-Old Female Volar Displaced Barton's Fracture

Virak Tan, MD
University of Medicine and Dentistry
Newark, NJ

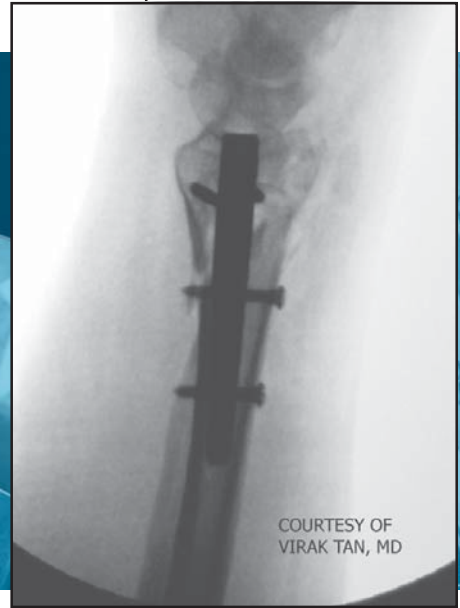PRE-OP



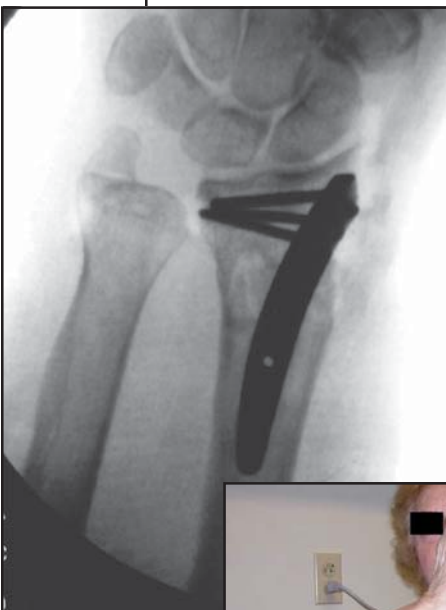
PRE-OP



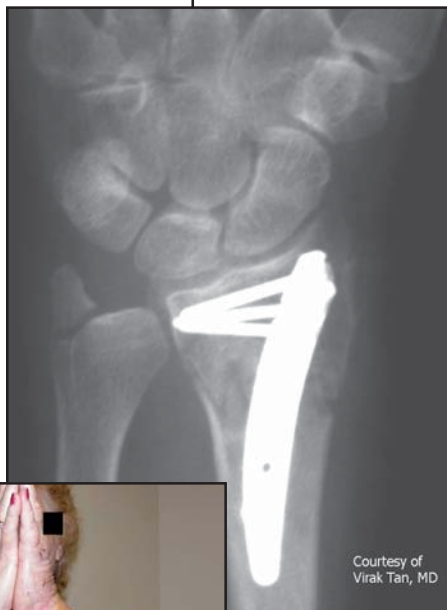IMMEDIATE POST-OP



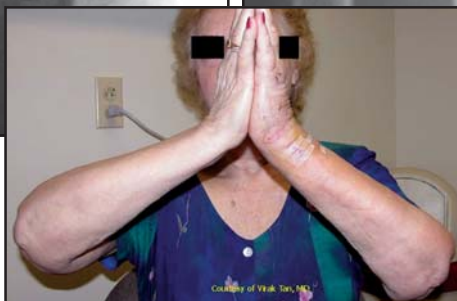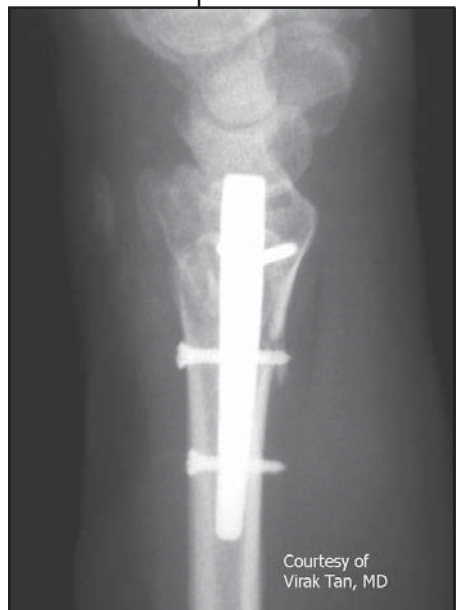IMMEDIATE POST-OP



2 WEEKS POST-OP



2 WEEKS POST-OP



Range of Motion
at just 2 weeks

