

TECHNICAL MONOGRAPH

# OSTEOSET<sup>®</sup>2 DBM

BONE GRAFT SUBSTITUTE WITH BIOASSAYED  
DEMINERALIZED BONE MATRIX

## PERFORMANCE CHARACTERISTICS OF OSTEOSET<sup>®</sup>2 DBM GRAFT

*Contains | BMP-2, BMP-4, IGF-1 and TGF- $\beta$ 1*



# **OSTEOSET® 2 DBM**

bone graft substitute with  
DEMINERALIZED BONE MATRIX

PERFORMANCE CHARACTERISTICS



technical monograph

# OSTEASET® 2 DBM

bone graft substitute with  
DEMINERALIZED BONE MATRIX

PERFORMANCE CHARACTERISTICS  
OF OSTEASET® 2 DBM GRAFT

## introduction

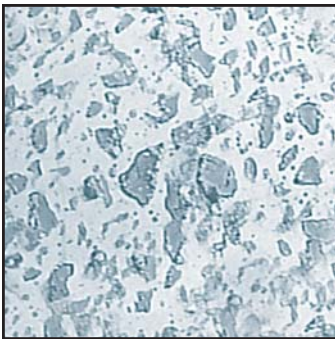
OSTEASET® 2 DBM pellets represent the next generation of product from Wright combining the clinical successes of both demineralized bone matrix and proprietary OSTEASET® 2 surgical grade calcium sulfate. A cross-sectional view of an OSTEASET® 2 DBM pellet shows demineralized bone matrix particles homogeneously dispersed throughout surgical-grade calcium sulfate. | **FIGURE 1**

This combination product is a resorbable bone graft substitute which acts as a scaffold for new bone formation. Demineralized bone matrix has been reported to provide osteoinductive bone morphogenetic proteins (BMPs) that signal precursor cells and stimulate the formation of bone at a defect site.

## background

Demineralized bone matrix has been used in conjunction with surgical grade calcium sulfate for many years. In 1992, Sottosanti<sup>6</sup> used a composite of demineralized bone matrix and calcium sulfate for regeneration of bone in extraction and periodontal defects. The calcium sulfate enhanced the inductive effect of demineralized bone matrix and provided a barrier to prevent connective tissue and epithelial invasion within the graft.<sup>7</sup> Sottosanti described numerous case studies in which 90% of his cases provided at least 80% bone filling confirmed by radiographs and re-entry techniques.<sup>8</sup>

The functions of calcium sulfate as part of a bone graft composite have been summarized by Sottosanti,<sup>9</sup> “The first is that it acts as a binder to improve the handling properties of the demineralized bone matrix powder, and limit particle loss. The second is that it improves the yield of new bone by enhancing the inductive effect of the available bone morphogenetic protein (BMP).” Wilkins and Kelly<sup>10</sup> reported the use of calcium sulfate and bioassayed demineralized bone matrix for bone grafting procedures in sites including the tibia, femur, and humerus. The combination of calcium sulfate and bioassayed demineralized bone matrix (DBM) produced an effective treatment for 25 patients with benign bone lesions, non-unions, and defects from osteomyelitis. Wilkins and Kelly conclude that, “The combination of human-derived growth factors found in bioassayed DBM and CaSO<sub>4</sub> appears to be an extremely effective material with which to graft space-occupying lesions of bone.”



**FIGURE 1** | Cross-sectional view of OSTEASET® 2 DBM pellet shows DBM particles homogeneously dispersed throughout the calcium-sulfate (Mag. 15.4x)

---

**“The combination of human derived growth factors found in bioassayed DBM and CaSO<sub>4</sub> appears to be an extremely effective material with which to graft space-occupying lesions of bone.”**

- WILKINS, R. AND KELLY, C.

“Human-derived growth factors and calcium sulfate use in grafting space occupying lesions of bone.”

*Trans. 10th International Symposium on Limb Salvage.*

---

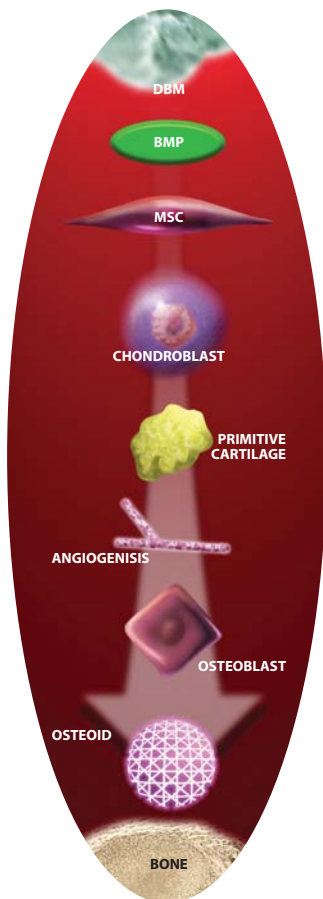
## OSTEOINDUCTION, BONE MORPHOGENETIC PROTEINS, AND GROWTH FACTORS

Demineralized bone matrix is made up of insoluble collagen and proteins that are non-collagenous in nature.<sup>11,12</sup>

Urist isolated bone morphogenetic protein (BMP) and declared it partially responsible for bone cell differentiation and the inductive nature of demineralized bone matrix.<sup>13,14</sup> Urist also found that the minerals in bone shield the BMPs from signaling bone induction, therefore the demineralization process enables the insoluble BMPs to induce bone formation.<sup>15</sup> A range of BMPs signal the cascade of bone formation that takes place at a defect site.<sup>12</sup> The bone matrix proteins signal mesenchymal stem cells to transform into osteoprogenitor cells to produce new bone growth.<sup>16</sup>

Reddi *et al.*<sup>17</sup> indicate that multiple BMPs have been identified in demineralized bone matrix, including proteins such as BMP-3 (osteogenin) and BMP-7 (osteogenic protein 1 - OP1). These proteins start the induction cascade of chemotaxis which is “the directed migration of cells in response to a chemical gradient of signals released from insoluble demineralized bone matrix”. Then fibroblasts proliferate, and cells differentiate.<sup>17</sup> There are a host of growth factors besides BMPs in bone matrix that may play a role in the formation and remodeling of bone.<sup>18</sup> It is not known the exact role growth factors play in bone cell differentiation, but they all may influence proliferation or differentiation of bone cells.<sup>19</sup> Bone matrix growth factors include TGF- $\beta$  (transforming growth factor beta), IGF-II (insulin like growth factors), acidic FGFs (fibroblast growth factors), basic FGFs, PDGFs (platelet derived growth factors), interleukins, granulocyte colony stimulating factors, and granulocyte macrophage colony stimulating factors, along with BMPs.<sup>18</sup>

While proteins in demineralized bone matrix provide an osteoinductive effect, the collagen structure in demineralized bone matrix provides an osteoconductive effect.<sup>20</sup> The osteoconductive and osteoinductive properties of DBM are important,<sup>20</sup> but it is its inductive nature that enables regeneration to occur throughout a defect rather than simply at the edges.<sup>4</sup>



**FIGURE 2** | DBM Mechanism of Action

### DBM MECHANISM OF ACTION

A description of the events following the mesenchymal stem cell attraction to the bone matrix follows:<sup>22,23</sup> | **FIGURE 2**

- Surface of the demineralized bone particles is lined with mesenchymal cells.
- Chondrogenesis occurs where mesenchymal stem cells transform to chondroblasts (cartilage cells).
- Angiogenesis occurs where new blood vessels are formed. Hypertrophy and mineralization occur in the cartilage.
- Osteoblasts form bone and marrow.
- New bone and demineralized bone particles are incorporated and remodeled.

This process of bone growth associated with demineralized bone matrix is called endochondral ossification in which cartilage forms prior to bone.<sup>24,25</sup> Zhang *et al.*<sup>20</sup> report, “In general, implantation of demineralized bone matrix evokes a transient inflammatory phase (day 1), followed by migration and proliferation of mesenchymal progenitor cells (days 2 through 4) which in turn differentiate into chondroblasts (days 5 through 7) and produce cartilage matrix that becomes calcified on days 11 or 12. After the cartilage becomes mineralized, it is invaded by vessels and chondrolysis begins. Eventually, the cartilaginous tissue is replaced by osseous tissue following the appearance of osteoblast-like cells.”

### TESTING AND SAFETY | TERMINAL STERILIZATION

OSTEOSET® 2 DBM pellets are terminally sterilized by validated electron beam sterilization. E-beam sterilization ensures the biological sterility of the product.

Wright works in partnership with the tissue banks to produce bioassayed human demineralized bone matrix of the highest quality. OSTEOSET® 2 DBM contains demineralized cortical bone powder that is routinely assayed for osteoinductive potential.

**EACH LOT OF DBM IS TESTED.** This bioassay ensures that demineralized bone matrix released for use and included in Wright products has documented osteoinductive potential.

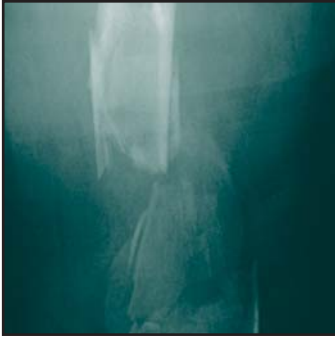

FIGURE 3A |

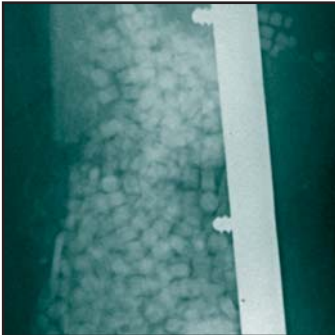


FIGURE 3B |

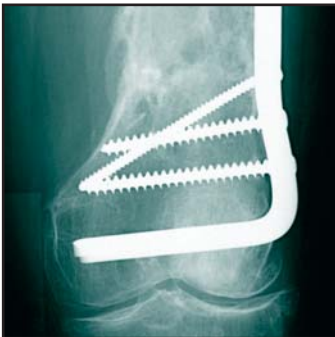

FIGURE 3C |

As with any allograft, there is a risk of disease transmission. Sottosanti<sup>6</sup> has stated, “There has never been a case reported of bacterial or viral transmission resulting from the use of DFDBA. Alcohol washes, acid demineralization, and the freeze-drying process make it impossible for bacteria or viruses to survive...” In addition, a study by Prewett *et al.*<sup>26</sup> suggests the acid demineralization process inactivates and eliminates HIV. There have been no documented cases of HIV transmission through the use of demineralized freeze dried bone allograft.

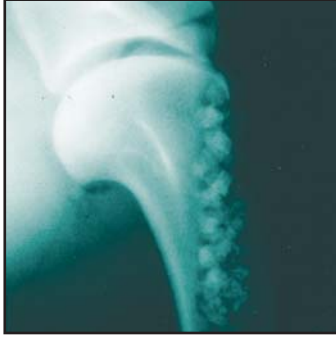
The DBM in Wright products has been validated to provide several logs of reduction for each of the five model viruses evaluated, including enveloped and non-enveloped viruses. This validation was accomplished by Wright’s performance of an extensive testing program to evaluate viral inactivation resulting from the various stages of the tissue processing. Focus was placed on the sterilization process as well as acid and alcohol washes used during the demineralization process. The validation protocol was particularly stringent as it employed analysis of the worst-case conditions for the series of processes potentially affecting and reducing the activity of viruses. The conclusion from the testing was that the overall process was effective in inactivating viruses.

Wright, as well as all of its tissue suppliers, are accredited by the American Association of Tissue Banks (AATB), a non-profit cooperative. Donors are screened rigorously using AATB and FDA standards, which includes thorough donor history, microbiological, and serological testing for diseases such as HIV, Hepatitis B and C. The AATB continuously evaluates improved testing and screening methods for allograft materials. The medical directors review each donor chart twice to ensure the safety and quality of Wright Medical’s products.

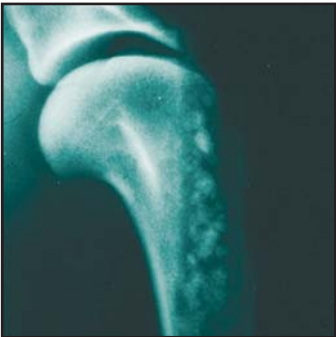#### EFFICACY

OSTEOSET® 2 DBM pellets offer a biological framework into which a patient’s own bone can grow. The pellets are resorbed at a rate consistent with the new bone growth (an average of 4-8 weeks).

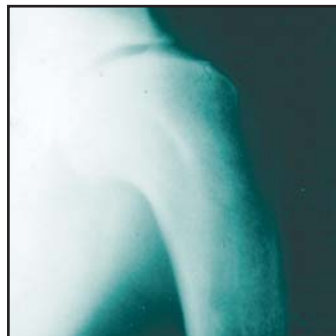The effectiveness of OSTEOSET® 2 DBM pellets can be illustrated by the following case of a 58-year old female who sustained a supracondylar fracture. | **FIGURE 3A** OSTEOSET® 2 DBM pellets were utilized as the primary grafting material | **FIGURE 3B** The radiograph taken at one year demonstrates the resorption of the pellets with excellent bone healing response. | **FIGURE 3C**



**FIGURE 4A** | Radiograph taken immediately after implantation of OSTEOSSET® 2 DBM pellets in a surgically created canine humeral defect.



**FIGURE 4B** | Radiograph taken at 2 weeks showing resorption of the OSTEOSSET® 2 DBM pellets with a corresponding increase in bone density along the original bone defect.



**FIGURE 4C** | Radiograph taken at 6 weeks showing further resorption of the OSTEOSSET® 2 DBM pellets and the formation of new bone within the original defect.

The crystalline form of the calcium sulfate material in OSTEOSSET® 2 DBM pellets is described as surgical grade alpha-hemihydrate. The surgical grade alpha-hemihydrate calcium sulfate is critical for consistent bone response. The crystalline structure, composition, and particle size distribution resulting from the use of the alpha-hemihydrate are the functional attributes contributing to the controlled resorption and uniform bone response.

The OSTEOSSET® 2 pellet manufacturing process creates a uniform crystalline structure of specific size and shape resulting in a controlled resorption rate and sustained release of growth factors to aid in the process of new bone formation.

Non-surgical grade calcium sulfates may resorb too rapidly, preventing creeping substitution of new woven bone. Conversely, slow resorption of non-surgical grade calcium sulfate may inhibit new bone growth. For these reasons, the use of non-surgical forms of calcium sulfate have historically resulted in sporadically successful outcomes.<sup>27,28</sup>

#### PRECLINICAL RESULTS

A canine model<sup>30</sup> was used to evaluate OSTEOSSET® 2 DBM pellets compared to demineralized bone matrix alone. This model has been used previously to evaluate OSTEOSSET® pellets and utilizes a surgically created 13 x 50 mm cylindrical cavity in the proximal humerus. The cavity in one limb was then filled with E-beam sterilized OSTEOSSET® 2 DBM pellets (made with canine demineralized bone matrix) and the contralateral limb was filled with aseptically prepared fresh frozen canine demineralized bone matrix. New bone formation was followed radiographically and histologically over a 6 week time period.

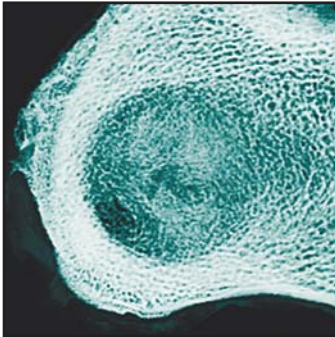
The plain film radiograph in | **FIGURE 4A** shows a well defined cylindrical defect filled with OSTEOSSET® 2 DBM pellets immediately after surgery. | **FIGURE 4B** demonstrates radiographically the same defect with partially resorbed pellets after two weeks. The radiograph indicates increased bone density compared to the immediate post-op radiograph, demonstrating concurrent new bone formation. | **FIGURE 4C** illustrates the OSTEOSSET® 2 DBM pellet defect at six weeks, radiographically indicating that the pellets have been resorbed and replaced by new bone.

**RAPID REMODELING**

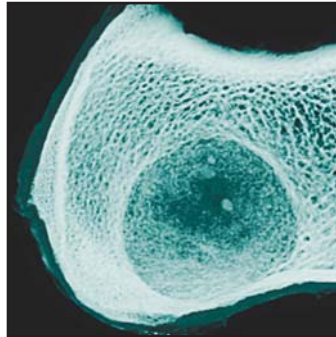
**FIGURE 5A** | Illustrates a contact radiograph at 6 weeks for the OSTEOSSET® 2 DBM pellets and | **FIGURE 5B** depicts demineralized bone matrix alone.

| **FIGURES 5C** and | **FIGURES 5E** illustrate autograft and a non-grafted control defect respectively. **FIGURE 5E** | reveals a well developed network of fine and coarse trabeculae interconnecting struts fully occupying the entire defect at 26 weeks.

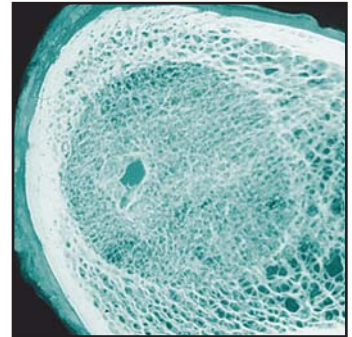
In the OSTEOSSET® 2 DBM graft example | **FIGURE 5A** remnants of pellets are slightly visible with new bone evident and significant improvement in organization of trabecular architecture compared with DBM and non-grafted controls. The void filled with demineralized bone matrix alone | **FIGURE 5B** appears to be consistently filled with new, immature bone in a more random trabecular formation with radiodensity less than adjacent bone or OSTEOSSET® 2 DBM pellet treated defects.



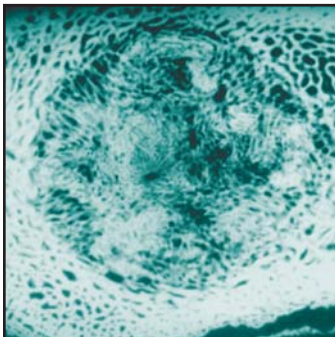
**FIGURE 5A** | OSTEOSSET® 2 DBM pellet site at six weeks demonstrating concentric lamellar bone formation and organized trabecular pattern throughout the defect



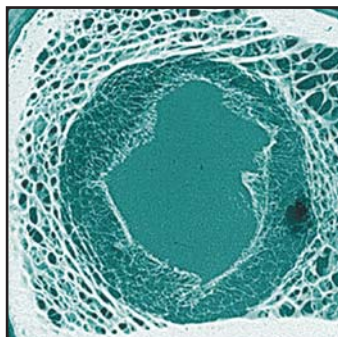
**FIGURE 5B** | Demineralized bone matrix alone at six weeks shows the defect filled with new, immature bone in a more random trabecular pattern and a radiodensity less than the adjacent bone or pellet treated defects



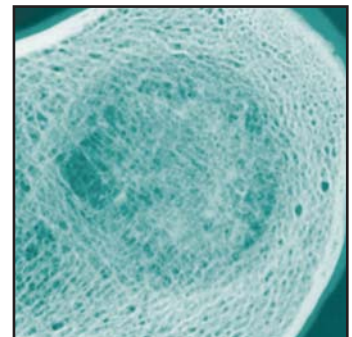
**FIGURE 5C** | Autograft at six weeks



**FIGURE 5D** | OSTEOSSET® Pellet alone at six weeks

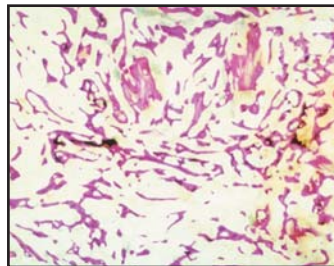


**FIGURE 5E** | Six week non-grafted control defect contains slender trabeculae at the periphery with the central aspect filled only with fibrous tissue

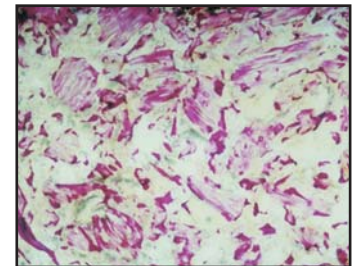


**FIGURE 5F** | OSTEOSSET® 2 DBM pellet site at twenty six weeks reveals a well developed network of fine and coarse trabeculae with interconnecting struts fully occupying the entire defect and contiguous with adjacent medullary bone

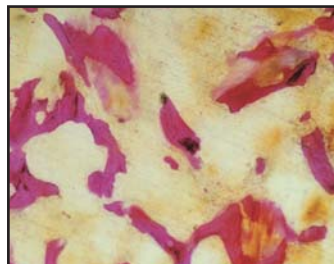
The histological results from the canine humeral model with OSTEOSET® 2 DBM pellets show abundant new trabecular bone formation throughout the defects at six weeks. | **FIGURE 6A** shows a site treated with OSTEOSET® 2 DBM pellets filled with new immature woven bone with a small amount of residual calcium sulfate and DBM particles remaining in the defect. Conversely, | **FIGURE 6B** demonstrates the demineralized bone matrix alone treated site where a large number of demineralized bone matrix particles are evident within the defects and new bone formation is found predominately at the margins and haversian surfaces of the matrix particles. OSTEOSET® 2 DBM pellets in | **FIGURE 7A** illustrate the new bony trabeculae incorporating residual calcium sulfate and demineralized bone matrix particles. The trabeculae are thickened and their surfaces show primarily osteoblastic activity. | **FIGURE 7B** represents the demineralized bone matrix alone site where the associated trabeculae are thinner. OSTEOSET® 2 DBM pellets consistently created a more dense and well-developed trabecular network



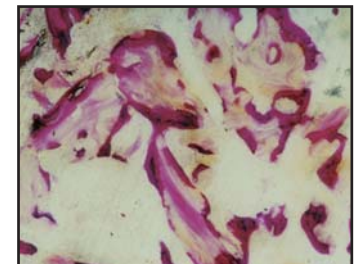
**FIGURE 6A** | At six weeks, histological section of site treated with OSTEOSET® 2 DBM pellets. Humeral defect filled with new bony trabeculae (Mag 3x)



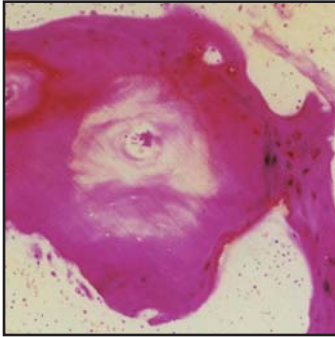
**FIGURE 6B** | Histological section of site treated with DBM (alone) with new bone formation predominately at the margins (Mag 3x)



**FIGURE 7A** | Newly formed, thickened trabeculae with prominent osteoblastic activity surrounding residual DBM particles and calcium sulfate in this OSTEOSET® 2 DBM pellet section. No evidence of foreign body reaction, granulomas, or abnormal giant cells (Mag. 13x)

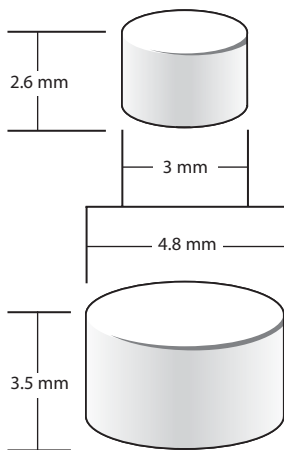


**FIGURE 7B** | DBM (alone) section showing thinner trabeculae than the defects treated with OSTEOSET® 2 DBM pellets. No evidence of foreign body reaction, granulomas, or abnormal giant cells (Mag. 13x)



**FIGURE 8 |** New bone formation surrounding a demineralized bone matrix particle in an OSTEASET® 2 DBM pellet treated site (Mag 39x)

**FIGURE 8 |** Provides a representative section of new bone formation surrounding a demineralized bone matrix particle within an OSTEASET® 2 DBM pellet section. Residual OSTEASET® 2 DBM material was incorporated by new bone formation with no evidence of foreign body reaction, granulomas, abnormal giant cells, or inflammatory cells.



**FIGURE 9 |**

**PRODUCT PARAMETERS**

OSTEOSET® 2 DBM pellets are available in two sizes. | **FIGURE 9** The smaller pellet is ideal for use in smaller bone defects. Each 4.8 mm and 3.0 mm pellet weighs approximately 80 mg and 25 mg, respectively. Pellets are packaged in several sizes for convenience. All pellets are packaged in vials or disposable injectors and electron beam sterilized.

PLEASE REFER TO THE OSTEOSET® 2 DBM PELLETS PACKAGE INSERT FOR ADDITIONAL INFORMATION RELATED TO WARNINGS, PRECAUTIONS, CONTRAINDICATIONS, AND ADVERSE REACTIONS.



## REFERENCES

1. Senn, N., "On the healing of aseptic bone cavities by implantation of antiseptic decalcified bone," *Amer. J. Med. Sciences*, 98:219-243, 1889.
2. Harakas, N. "Demineralized bone-matrix-induced osteogenesis," *Clin. Orthop. Rel. Res.*, 188:239-251, 1983.
3. Urist, M., "Bone: Formation by autoinduction," *Science*, 150: 893-899, 1965.
4. Mulliken, J., Glowacki, J., Kaban, L., Folkman, J., and Murray, J. "Use of demineralized allogeneic bone implants for the correction of maxillofacial deformities," *Ann. Surg.*, 194:366-372, 1981.
5. Tiedman, J., Garvin, K., Kile, T., and Connolly, J., "The role of a composite, demineralized bone matrix and bone marrow in the treatment of osseous defects," *Orthopedics*, 18:1153-1158, 1995.
6. Sottosanti, J., "Calcium sulfate: a biodegradable and biocompatible barrier for guided tissue regeneration," *Compendium*, 13:226-234, 1992.
7. Sottosanti, J., "Aesthetic extraction with calcium sulfate and the principles of guided tissue regeneration," *Pract. Periodont. Aesthet. Dent.*, 5:61-69, 1993.
8. Sottosanti, J., "Calcium sulfate-aided bone regeneration: A case report," *Periodont. Clin. Invest.*, 17: 10-15, 1995.
9. Perel, M., "Calcium sulfate is a safe, resorbable barrier adjunct to implant surgical procedures," Interview with J. Sottosanti, *Dental Implantology Update*, 4:69-76, 1993.
10. Wilkins, R. and Kelly, C.: "Human-derived growth factors and calcium sulfate use in grafting space-occupying lesions of bone." *Trans. 10th International Symposium on Limb Salvage*.
11. Mulliken, J., Kaban, L., and Glowacki, J., "Induced osteogenesis - The biological principle and clinical applications," *J. Surg. Res.*, 37:487-496, 1984.
12. Yazdi, M., and Schonfeld, S., "Demineralized bone matrix in treatment of periodontal defects. A review of the literature," *J. Western Soc. Periodont.*, 35:105-108, 1987.
13. Urist, M. and Strates, B., "Bone morphogenetic protein," *J. Dent. Res.*, (Suppl. 6) 50:1392, 1971.
14. Urist, M., DeLange, R., and Finerman, G., "Bone cell differentiation and growth factors," *Science*, 220: 680 - 686, 1983.
15. Urist, M. and Strates, B., "Bone formation in implants of partially and wholly demineralized bone matrix," *Clin. Orthop. Rel. Res.*, 71: 271-278, 1970.
16. Covey, D., and Albright, J., "Clinical induction of bone repair with demineralized bone matrix or a bone morphogenetic protein," *Orthop. Rev.*, 18:857-863, 1989.
17. Reddi, A., "Initiation of fracture repair by bone morphogenetic proteins," *Clin. Orthop. Rel. Res.*, 355S:66-72, 1998.
18. Stevenson, S., "Enhancement of fracture healing with autogenous and allogeneic bone grafts," *Clin. Orthop. Rel. Res.*, 355S:239-246, 1998.
19. Muschler, G. and Lane, J., "Orthopedic surgery," *Bone Grafts and Bone Graft Substitutes*, Ch.32:375-407, edited by Habal, M., and Reddi, A., 1992.
20. Zhang, M., Powers, R., and Wolfenbarger, L., "A quantitative assessment of osteoinductivity of human demineralized bone matrix," *J. Periodontol.*, 68:1076-1084, 1997.
21. Adkisson, H.D., Strauss-Shoenberger, J., Gillis, M., Wilkins, R., Jackson, M., and Hruska, K.A., "A rapid quantitative bioassay of osteoinduction," submitted for publication.
22. Sonis, S., Kaban, L., Glowacki, J., "Clinical trial of demineralized bone powder in the treatment of periodontal defects," *J. Oral Med.*, 38:117-122, 1983.
23. Reddi, A., "Implant stimulated interface reactions during collagenous bone matrix induced bone formation," *J. Biomed. Mat. Res.*, 19:233-239, 1985.
24. Glowacki, J. and Mulliken, J. "Demineralized bone implants," *Clin. Plas. Surg.*, 12:233-241, 1985.
25. Kaban, L., Mulliken, J., and Glowacki, J., "Treatment of jaw defects with demineralized bone implants," *J. Oral Maxillofac. Surg.*, 40:623-626, 1982.
26. Prewett, A., Moyer, M, O'Leary, R., and Mellonig, J., "Decalcification inactivates HIV in spiked and infected bone," *ORS Transactions*, 436, 1992.
27. Dreesmann, H., "Ueber knochenplombierung," *Beitr. Klin.Chir.*, 9:804, 1892.
28. Peltier, L.F., "The use of plaster of Paris to fill defects in bone," *Clin. Orthop. Rel. Res.*, 21:1-31, 1961.
29. United States Patent #5,516,206, March 24, 1997.
30. Turner, T.M., Urban, R.M., Gitelis, S., Infanger, S., Berzins, A., and Hall, D.J., "Efficacy of calcium sulfate, a synthetic bone graft material, in healing a large canine medullary defect." 45th Orthopaedic Research Society Meeting, Anaheim, CA, 1999.



### Wright Medical Technology, Inc.

5677 Airline Road  
Arlington, TN 38002  
901.867.9971 phone  
800.238.7188 toll-free  
www.wmt.com

### Wright Cremascoli Ortho SA

Zone Industrielle la Farlecle  
Rue Pasteur BP 222  
83089 Toulon Cedex 09  
France  
011.33.49.408.7788 phone

™Trademarks and ®Registered marks of Wright Medical Technology, Inc.  
Covered by one or more of the following patents.  
US Patents 5,614,206; 5,807,567; 6,030,636. Patents pending.  
© 2004 Wright Medical Technology, Inc. All Rights Reserved.

SK 957-899  
Rev.05.04